

## Clinical Image

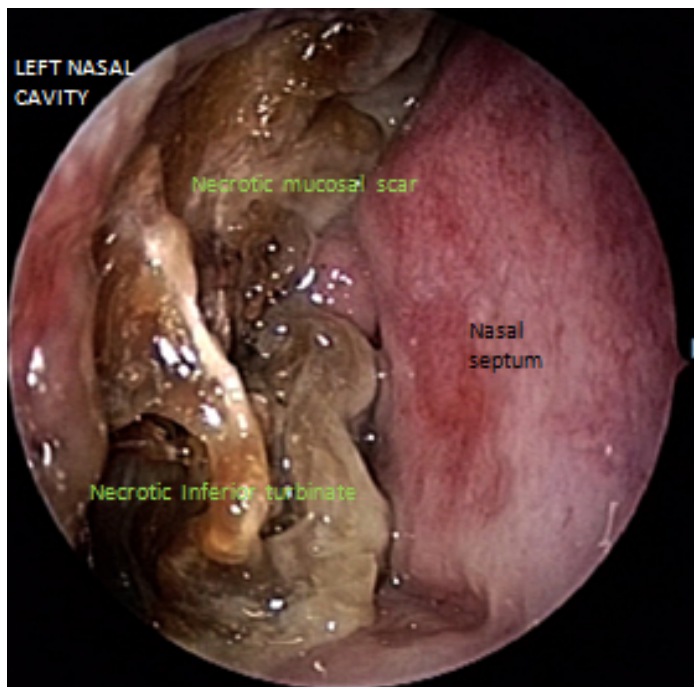
# Granulomatosis with Polyangiitis (Wegener's) with nasal manifestation

Running title: Persistent sinusitis with necrotic intranasal mucosa

**Athanasios Saratziotis**

Head and Neck Surgery ENT Department, Faculty of Medicine, School of Health Sciences, University of Thessaly, University General Hospital of Larissa, 40110 Larissa, Greece  
Corresponding Author's e-mail: asaratziotis@gmail.com

**Keywords-** Wegener's granulomatosis; necrotic nasal mucosa; nasal obstruction



**Image 1.** The typical manifestation of primary necrotizing vasculitis was persistent nasal obstruction in an adult patient with no history of nasal disorder. In the endoscopic intranasal examination may reveal only diffuse nasal mucosal destruction and in advance manifestation of the disease with necrotic areas. The mucosa may be dry, crusted and the tissue around and underlying the crusts is extremely friable. Perforations of the nasal septum are also common. In this case, manifestation was unilateral co involved inferior and middle turbinate in the left nasal cavity with intact nasal septum. A diagnosis of Granulomatosis with Polyangiitis requires a history of chronic inflammation for at least four weeks which is not due to another cause. Adequate biopsy of representative tissue is important as well as an autoimmune serology manifesting the presence of disease related C-ANCA/anti-PR3 (ANCA)

### AUTHORS CONTRIBUTION

The author prepared the manuscript and the artwork. The author approves the final version of the manuscript.

### CONFLICT OF INTEREST

The Author declares no conflict of interest